



STR Newsletter

Summer 2008

Editor: David A. Lynch, MD

2009 STR Annual Meeting as Part of WCTI-II

In This Issue:

- 2009 Annual Meeting in Spain
- 2010 Annual Meeting Venue
- 2008 Annual Meeting Photos
- RSNA Workshop On Structured Radiology Report
- STR Case of the Day

The second World Congress of Thoracic Imaging (WCTI-II) will be held May 30-June 2, 2009 in Valencia, Spain. This Congress will be sponsored by the STR, Fleischner Society, European Society for Thoracic Imaging, Japanese Society of Thoracic Imaging, and Korean Society of Thoracic Imaging.

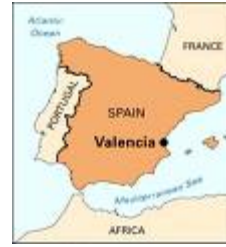The Palacio de Congreso will be the Congress venue. Dr. Jose Vilar is chair of the Congress, with active committees representing all the participating societies. The program and registration information can be found on the Congress website <http://www.2wcti.org>. The call for abstracts of scientific presentations and educational exhibits can be submitted now until January 15, 2009 on the Congress website.

The STR has blocked 70 rooms at the Hilton Valencia Hotel specifically for STR members. In order to register and reserve a room, STR members should complete and submit the World Congress Registration form as instructed on their website.



*Palacio de Congreso
Valencia, Spain*

Valencia Pictures



Crown Room at Hotel del Coronado



Garden Patio at Hotel del Coronado



Beach and Pool at Hotel del Coronado

2010 STR Annual Meeting Venue


After careful review, the STR has identified the site for the 2010 Annual Meeting. It will be held at the Hotel del Coronado in San Diego, California from February 28 through March 3, 2010. As members may recall, this historic hotel is superbly situated on the beach on Coronado Island, about 20 minutes from the airport. The hotel rooms and meeting space have been completely renovated since the Society's last visit there in the late 90's.



Hotel del Coronado and Pacific Ocean – San Diego, CA

2008 Annual Meeting Photos

Below are photos taken at the March 2008 STR Annual Meeting at Sanibel Harbour Resort & Spa in Fort Myers, Florida.



STR Officers (2008-2009)

President

Jannette Collins,
MD, MEd

President-Elect

Charles S. White,
MD

Secretary

David A. Lynch, MD

Treasurer

Gerald F. Abbott,
MD

Search for the New JTI Editor

The search for a new editor of JTI is progressing, and announcement of the new editor is expected soon.

RSNA Workshop on the Structured Radiology Report

June 17-18, 2008
By Loren Ketai, MD

In mid-June RSNA convened a two day workshop on the development of structured radiology reporting. The goal of the meeting was to advance radiology's adoption of a structured report and begin building a consensus on what that report should look like. Like a warmer planet, structured radiology reports look to be an inevitable part of the future.

Why Structured Reporting?

The move to structured reporting is driven in part by forces outside of radiology.

Interested in increasing your participation in the STR?

STR committees foster growth and excellence in the field of cardiothoracic imaging.

Participation on an STR committee does make a difference!!

These forces include Physician Quality Reporting Initiatives (PQRI) from the Centers for Medicare and Medicaid Services (CMS) and from pay for performance initiatives directed by various third party payers. Regulations originating from other specialties may also drive the process forward, as it has for pathology, where American College of Surgeons mandates for hospital accreditation spurred pathologists to adopt structured reports.

Although it may be driven forward by regulation, akin to the mammography quality standard assurance (MQSA), adoption of structure reporting can benefit radiologists and clinicians. Structured reports offer the opportunity to improve the clarity of information available to the referring physician and facilitate more rapid communication of urgent and emergent findings. By using standardized headings and data elements radiologists can also prevent inadvertent omissions, improve the accuracy of speech recognition and assist the integration of decision analysis tools.

Structured reporting can also facilitate radiology department driven data mining for use in quality assurance projects and research. For instance a well designed standardized report might allow one to answer the following: When reading two view chest radiographs how often does Physician A recommend chest CT for further evaluation of a lung nodule or mass? How often do the resulting CTs show a non-calcified nodule or mass? How does Physician A compare to physicians B and C?

What Constitutes a Structured Report?

The structured radiology report will be built from templates that contains standardized headings; A proposed general format for headings is:

Patient identifiers, Demographics

Clinical information

Includes statement for medical necessity

Imaging technique, Procedure

Medications administered (e.g. intravenous contrast)

Equipment used

Radiation dose

Comparison, Previous exams

Image quality (Optional)

Observations, Findings

Summary or Impression

Complication (Optional)

Recommendations (Optional)

Selection of individual data elements within each of the headings will be more complex, particularly under the headings of "Findings" and "Impressions". Under the header of findings, for example, the predetermined data elements will need to vary depending on exam type, broad for a chest radiograph, (e.g. Mediastinum) and more specific for a CT angiogram (segmental pulmonary arteries). Cardiac imaging terms have already been designated by consensus among multiple societies (NASCI, SCCT, SCMR, etc.), using a more in depth vocabulary than currently available in RadLex. Once terms such as these are designated, the data elements in the report can be filled in using either free text (synoptic-like reporting) or designated from a drop down menus (true synoptic reporting). Either method, free text or drop down menus, might also include standardized modifiers for degree of reader certainty.

With structured reporting the most critical portion of the report remains the information communicated under the "Impression" header. An ideal system would

Society of Thoracic
Radiology
c/o Matrix Meetings,
Inc.
P.O. Box 7169
Rochester, MN 55903-
7169

Phone:
(507) 288-5620
Fax:
(507) 288-0014

E-mail:
str@thoracicrad.org
Website:
www.thoracicrad.org

contain specific diagnostic summary codes akin to the BIRADS classification of mammography. This will be challenging in reporting on more complex organ systems where the clinical impression can not be crystallized to "Cancer/Not cancer/Maybe". If attainable in thoracic imaging, however, these structured impressions could be used to speed communication about the diagnosis of diseases that require immediate treatment or are life-threatening. An impression created from standard terms could also automatically generate multiple reports with different annotations/explanations, depending on the recipient (e.g. Family Practitioner vs. Pulmonologist).

How Can We Move towards Structured Reporting?

In order for a structured reporting system to function well there will need to be a widely accepted method of encoding the report data so that it can be accurately exported to radiology information systems. This will require uniformity of field names and locations and a common ontology, a means of defining the relationships between these data elements. Field names, locations and ontology more likely to be uniform and successful if they originate from radiology societies than from individual vendors.

RSNA is exploring ways to move the adoption of structural reporting forward and ensure that the end product is optimized for radiologists. Initial models will likely focus on a (relatively) low volume high impact studies such as a CT of the body for trauma. Before that model can be crafted the society would like to develop a generalized format for template construction, i.e. a template for templates. Towards that end RSNA will be collecting suggested report templates for radiologic studies from the specialty societies. Specifically, the society is seeking sample macros created by academic institutions that are currently in use with speech recognition dictation.

The Society of Thoracic Radiology can assist in this effort by supplying suggested templates for thoracic imaging studies, ranging from PA and lateral chest radiographs to high resolution chest CTs. Initially the members of the STR Standards Committee will be requested to supply templates and the committee will attempt to reach a consensus on which templates to submit to the RSNA. It's important to note that these templates will be used by RSNA to work towards a common format for structured dictation. At this stage templates will not be "codified" to produce a standard for reporting analogous to ACR appropriateness criteria for study selection.

Conclusion

For now, we seem headed towards both a warmer planet and structured reporting. One will cause far reaching changes in the lives of most of the world's population; one looms large for only radiologists. Both can be better addressed if we start working on our own solutions in the present, rather than letting external forces determine the future in random and unpredictable ways.

STR Case of the Day

STR Case of the Day

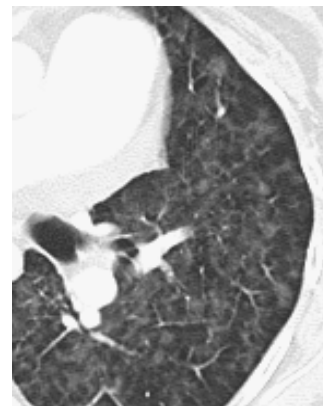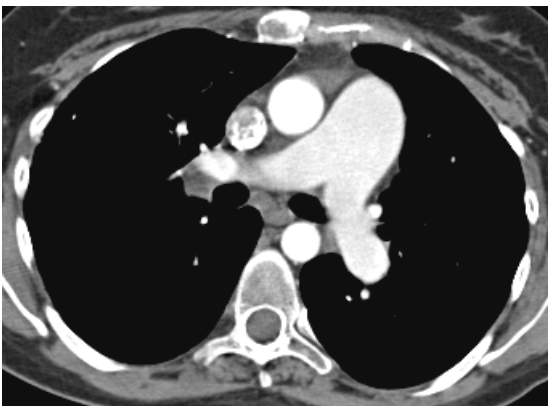
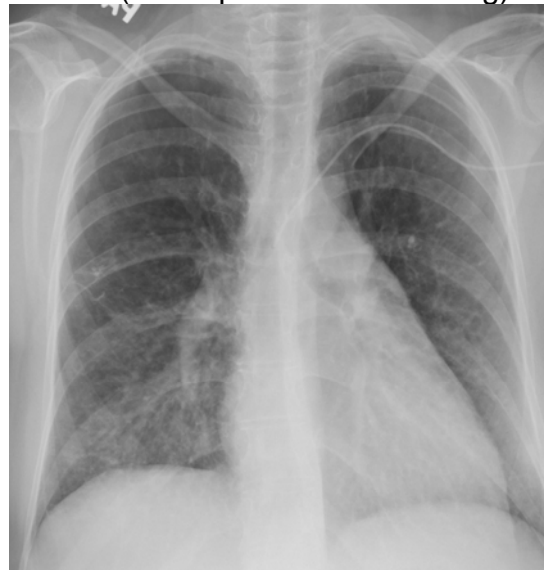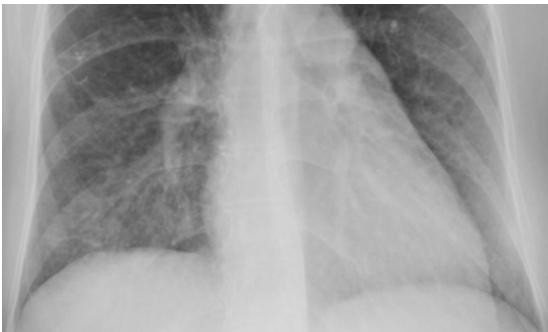Editor for Case of the Day: Ralph Drosten, MD

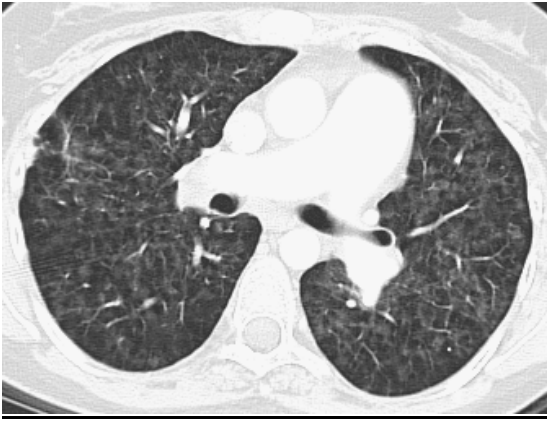
Presented by Brian C. Allen, MD and Tan-Lucien Mohammed, MD, FCCP
Cleveland Clinic Department of Radiology

- 26 year old female with progressive shortness of breath and dyspnea on exertion
- FEV1/FVC ratio reduced – Obstructive pattern
- DLCO significantly reduced – Alveolar capillary surface area for gas exchange is reduced
- Echocardiogram suggests pulmonary hypertension - right ventricle is dilated and hypokinetic. Normal left ventricular function
- Right heart catheterization - pulmonary arterial hypertension (mean pressure 46 mm Hg)

Chest Radiograph

- Faint, lower zone nodular opacities
- Enlarged central pulmonary arteries
- No pleural effusion





CT Thorax

- Dilated main pulmonary artery
- Prominent mediastinal and hilar lymph nodes
- Diffuse pulmonary nodules with subpleural sparing

Micropathology

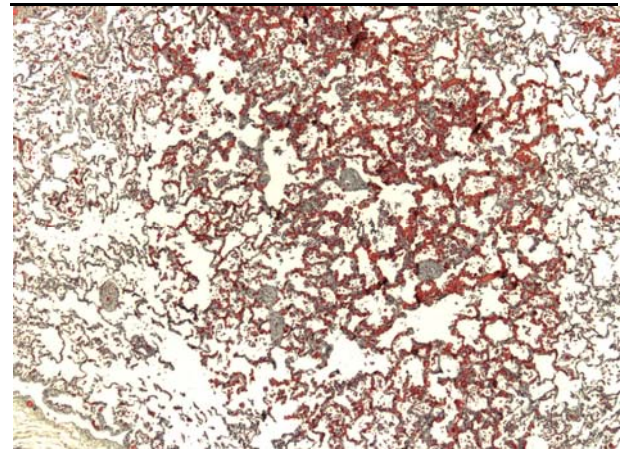
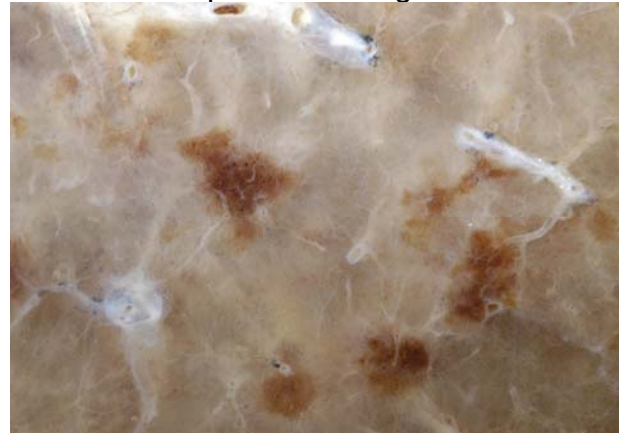- Dense, cellular capillary walls
- Normal lung interspersed
- No pulmonary venous occlusion

Differential Diagnosis

- Pulmonary veno-occlusive disease
- Pulmonary capillary hemangiomas
- Primary pulmonary hypertension
- Chronic pulmonary embolism

Gross Pathology

- Multiple, hemorrhagic nodules
- Mild septal thickening



Final Diagnosis

- Pulmonary capillary hemangiomas

Discussion

- Rare, idiopathic cause of post-capillary pulmonary hypertension
- Mean age = 30, Male = Female
- Median survival 3 years from presentation
- Weak association with SLE, scleroderma, Takayasu arteritis, Kartagener syndrome, hypertrophic cardiomyopathy
- Progressive dyspnea and fatigue
- Chronic cough, chest pain, syncope,

- Hemoptysis
- Hemorrhagic pleural effusions
- Progresses to right sided heart failure
- Often misdiagnosed as PPH, PVOD, pulmonary fibrosis, pulmonary thromboembolism, pulmonary hemosiderosis
- Plain film findings
 - Central pulmonary artery enlargement and prominence of the right ventricle
 - Diffuse or bibasilar nodular opacities
 - Pleural effusions and septal lines are rare
 - Occasional mediastinal lymphadenopathy
- HRCT
 - Main pulmonary artery enlargement
 - Occasional enlargement of the right heart
 - Wide-spread, ill-defined, GGO centrilobular nodules, may spare the subpleura
 - Septal thickening, lymphadenopathy, pleural and pericardial effusions are uncommon
- Pulmonary Angiogram
 - Usually normal
- Definitive diagnosis requires tissue biopsy
 - Surgical lung biopsy is gold standard
 - Pulmonary hypertension precautions
- Pathology - Gross
 - Multiple hemorrhagic appearing parenchymal nodules
 - Well-circumscribed, proliferative capillary lesions
- Pathology – Microscopic
 - Angioproliferative response to pulmonary venous hypertension
 - Capillary proliferation with normal lung interspersed
 - Capillary invasion into support structures leads to collapse of airways on expiration
 - Densely cellular alveolar walls, leads to decreased DLCO
 - No pulmonary venous occlusion
- Therapy
 - Only curative therapy is lung or lung-heart transplant
 - Pharmacologic therapy is supportive
 - Decrease pulmonary vascular resistance, increase cardiac output, reduce volume overload
 - Medications include ACE-I, cardiac glycosides, oxygen supplementation, vasodilators, immunosuppression
 - Severe, life threatening pulmonary edema with potent vasodilators
- Summary
 - Pulmonary capillary hemangiomatosis is a rare, idiopathic cause of pulmonary hypertension secondary to aberrant capillary growth
 - Pulmonary hypertension on x-ray. Diffuse centrilobular ground glass nodules on CT
 - Definitive diagnosis requires biopsy
 - Curative treatment includes lung transplantation

- Selected references

- El-Gabaly, M., et al: Pulmonary Capillary Hemangiomas Imaging Findings and Literature Update. *J Comput Assist Tomogr.* 31 (4): 608-610, 2007
- Frazier, A., et al: Pulmonary Veno-occlusive Disease and Pulmonary Capillary Hemangiomas. *Radiographics.* 27 (3): 867-882, 2007
- Lawler, L. and Askin, F.: Pulmonary Capillary Hemangiomas. *J Thorac Imaging.* 20 (2): 61-63, 2005
- Lantuejoul, S., et al: Pulmonary Veno-occlusive Disease and Capillary Hemangiomas. *Am J Surg Pathol.* 30 (7): 850-857, 2006